J. Oral Diagn 2026;11:e455
https://doi.org/10.5327/2525-5711.455

CASE REPORT

Desquamative gingivitis and its importance in the differential diagnosis of oral diseases by periodontists: a case report

Karine Duarte da Silva[1]*, Caroline Luiz Angonese[1], Bruno Moro de Barcelos[1], Karina Blanck Janke[1], Jeniffer Zettermann da Costa[1]

Abstract:

This study aims to report a case of pemphigus vulgaris with involvement of the oral mucosa, initially diagnosed as desquamative gingivitis, which was inadvertently treated as plaque-induced gingival disease. A 36-year-old female patient sought the periodontist complaining of painful oral lesions with a 6-month evolution. According to her, her "gums are peeling". She presented areas of erythema in the marginal gingiva, more visible in the lower anterior teeth region. Lesions were associated with edema and erosion, followed by ulceration. The condition was initially misdiagnosed and treated as necrotizing periodontitis. Thereafter, the patient searched for a stomatologist who found, in addition to desquamative gingivitis, ulcerated areas on the dorsum and lateral edges of the tongue. The clinical suspicion of immune-mediated disease was raised and from an incisional biopsy, the diagnosis "compatible with pemphigus vulgaris" was reached. Systemic corticosteroid therapy was introduced immediately after the biopsy, resulting in a considerable reduction of the lesions. The patient remains under medical and dental follow-up, without presenting oral or skin lesions at 6-year follow-up. Knowledge of the clinical aspects of PV and DG is essential to avoid misdiagnosis of oral diseases. Furthermore, the diagnosis of immune-mediated diseases should be encouraged among dentists.

Keywords: Autoimmune diseases; Gingival diseases; Mouth; Pemphigus.

INTRODUCTION

The gingiva can exhibit a variety of non-plaque induced lesions, which in some cases may be manifestations of a systemic condition[1-3]. Although these lesions are not directly caused by plaque, their clinical course can be impacted by plaque accumulation and subsequent inflammation[2]. Dentists must establish the diagnosis and formulate treatment plans for patients affected by such conditions; otherwise, the patient should be referred to appropriate treatment without delay[1,2].

Desquamative gingivitis (DG) can be found in different oral diseases, and it is characterized by inflammation and gingival erythema, which can progress to erosion and ulceration. Bleeding is commonly seen and DG can be localized or diffuse[1,4-6]. The clinical findings of DG can be subtle, which can lead to a late diagnosis of the associated disease[4].

Many patients with DG experience bleeding gums after brushing or eating. This sign is often interpreted as plaque-induced gingivitis, and patients are usually referred to conventional periodontal therapy, but this does not resolve the clinical condition[4,7,8]. In more severe cases, generalized desquamation occurs, leading to the loss of large fragments of gum, with frequent reports by the patient that "the gums are peeling"[2,9]. This condition is usually accompanied by pain and reduced oral intake, which can lead to dehydration and malnutrition, thus impacting the patient's quality of life[10].

A wide spectrum of diseases can be associated with DG, mainly mucous membrane pemphigoid (MMP), lichen planus (LP), and pemphigus vulgaris (PV). Less frequently, DG may also represent the oral manifestation of other immune-mediated or inflammatory disorders, such as linear IgA bullous dermatosis,

Statement of Clinical Significance
Lack of knowledge regarding the oral manifestations of autoimmune diseases can result in delayed diagnoses and inappropriate treatment approaches. Periodontists, in collaboration with other healthcare professionals, should enhance their understanding of this topic to ensure comprehensive and effective patient care.

[1]Centro Universitário Ritter dos Reis, School of Dentistry – Porto Alegre (RS), Brazil.
***Correspondence to:** E-mail: karineduartedasilva1@gmail.com
Received on January 23, 2026. Accepted on June 6, 2026.
https://doi.org/10.5327/2525-5711.455

epidermolysis bullosa acquisita, dermatitis herpetiformis, chronic ulcerative stomatitis, lupus erythematosus, paraneoplastic pemphigus, graft-versus-host disease, and hypersensitivity reactions to dental materials[2,9]. In some cases, DG is the only finding of the underlying condition. There is benefit from periodontal therapy in the temporary reduction of DG lesions, but the condition only has complete resolution when the underlying disease is diagnosed[8]. Late diagnosis and inadequate treatment of DG can lead to disease progression, new oral or extraoral lesions, increased treatment burden, and prolonged patient suffering[7,11].

The diversity of possible diagnoses for gingival lesions must be well known by dentists, especially periodontists[1]. Mucocutaneous diseases may have their first, and sometimes only, manifestations in the oral mucosa, reiterating the role of dentists in understanding systemic diseases that may affect the oral cavity[1,4,11].

Therefore, the objective of this study is to report a case compatible with pemphigus vulgaris with involvement of the oral mucosa, initially diagnosed as DG, which was inadvertently treated as plaque-induced gingival disease until the correct diagnosis and treatment were established. The rationale behind the study is to draw attention to the importance of dentists from different specialties having knowledge about immune-mediated lesions that can affect the oral mucosa, thus avoiding delays in diagnosis and inappropriate treatments.

CASE REPORT

Anamnesis

A 36-year-old female patient presented at the private dental clinic expressing difficulty in eating due to painful ulcers in the oral cavity within the past six months. The patient reported that some months ago, blisters appeared on the fingertips with subsequent rupture. She also reported previous use of topical corticosteroids (dexamethasone elixir) with little improvement and subsequent return of the lesions. The medical, family, and psychosocial history was unremarkable.

Oral examination

Intraoral examination revealed the presence of erosive and ulcerated areas, with painful symptoms in the gums and tongue (Figures 1 and 2), causing difficulty in speaking, swallowing, and chewing. The patient was initially diagnosed by a periodontist with necrotizing periodontitis. Thus, basic periodontal therapy was instituted, with antibiotic therapy in association with 0.12% chlorhexidine mouthwash. Amoxicillin 500 mg and metronidazole 750 mg were prescribed for 7 days. There was an initial improvement in the lesions with subsequent worsening (Figure 1C).

Management

An incisional biopsy of the dorsum of the tongue was performed. The histopathological diagnosis made by a medical pathologist indicated "acute and chronic ulcerated inflammation of the squamous mucosa". The report did not aid in the management of the case, and the patient progressed with worsening pain, especially on the lateral edges of the tongue. A new incisional biopsy in the lateral edge of the tongue was performed by a stomatologist, and the material was sent to an oral pathology laboratory, in addition to the use of dexamethasone elixir to relieve symptoms.

Diagnosis and treatment

When the new histopathological report revealed "compatible with pemphigus vulgaris," the patient could then be properly treated. Microscopic analysis revealed the formation of an intraepithelial cleft with several acantholytic cells, in addition to a single-layer epithelial lining with a tombstone appearance. The connective tissue of the lamina propria was hypervascularized and intensely infiltrated by inflammatory cells (Figure 3).

In the immediate postoperative period, the patient started using prednisone 40mg/day and dexamethasone elixir was also maintained until the medical appointment. Albendazole 400mg/day was used for three days at the start of systemic corticosteroid therapy. Figure 4 shows the results of a seven-day follow-up, revealing substantial remission of the lesions. As pemphigus vulgaris is a systemic condition, a medical referral was made.

Although immunofluorescence is recommended for confirming the diagnosis, in this particular case it was not possible to perform it due to costs and the distance between the city of the patient and the laboratory that performs the technique (300km).

The patient is still under medical and dental follow-up, using rituximab 500mg/50ml every year. She previously used prednisolone 5mg and 10mg every other day and rituximab 500mg/50ml every six months, but has not used systemic corticosteroids for 1 year. No adverse effects from the corticosteroid therapy have

been reported. Figure 5 shows the patient at a six-year follow-up. The gingiva and tongue showed no clinical abnormalities. The patient feels well and carries out her daily activities without limitations.

The timeline of the case can be seen in Figure 6.

The CARE checklist was used as a guide for reporting the case.

DISCUSSION

The case reported here is a classic form of PV, including a prolonged history of nonspecific dental care until a conclusive diagnosis was made[7]. Clinically, there was diffuse involvement of the marginal and papillary gingiva in the maxilla and mandible, with ulcers at the apex of the papillae, but without necrosis or inversion of the triangular aspect as would be seen in a necrotizing periodontal disease[4].

Pemphigus can be considered serious and even life-threatening. The name is used for a group of autoimmune mucocutaneous bullous diseases[11,12]. PV is the most frequent of the subtypes, comprising up to 70% of all cases of pemphigus, and has an uneven geographic and ethnic distribution around the world[12]. Its annual incidence can vary, from less than 1 per million inhabitants to around 16 per million inhabitants, depending on the population assessed[12].

Most studies report that PV is more common in females in their fifth and sixth decades of life, and classically starts with lesions in the oral mucosa, thus being of greater relevance in dental practice[1,11,13]. Generally, the first affected sites are those exposed to trauma due to friction, including the buccal mucosa, gums and the lateral edge of the tongue. However, PV can occur anywhere in the oral cavity[1,11,13]. PV is responsible for 3% to 15% of cases of DG among different



Figure 1. Presence of erosive (A) and ulcerated (B) areas in the upper and lower gum. (C) Swollen gum, showing improvement after periodontal therapy followed by worsening.

patient cohorts; and together with LP and MMP, they account for 80% of DG cases[4].

The clinical course observed in our patient is consistent with previously reported cases in which PV manifested predominantly or exclusively as DG[14,15]. Although the oral mucosa is affected in most patients with PV, a gingival presentation in the form of DG is comparatively uncommon and is more often associated with mucous membrane pemphigoid and oral lichen planus than with PV[4]. Migliari et al. recently reported a 37-year-old woman with a seven-month history of desquamative gingival lesions diagnosed as PV-associated DG, closely mirroring the demographic and temporal profile of the present 36-year-old patient[15]. A recurring feature across these reports, including the present one, is the initial misinterpretation of the gingival involvement as plaque-induced gingival disease, which delays diagnosis and the institution of appropriate therapy[11,16].

The lesions of PV begin as vesicles with a thin, friable roof that rupture easily, leaving erosions and ulcers. Oral and pharyngeal lesions make hydration and nutrition difficult, and may lead to weight loss and severe wasting. In addition, disruption of the skin barrier increases the risk of secondary infections and sepsis, which can lead to death[11,16]. Cutaneous involvement may appear several weeks or months after the appearance of mucosal lesions as flaccid blisters that end up as ulcers, justifying the need for concomitant medical follow-up[11]. During follow-up, the studied patient did not present skin lesions.

The mortality rate tends to decrease if there is an early diagnosis[12]. In the reported case, initial clinical examination shows edema and bleeding of the papillae, raising the hypotheses of necrotizing periodontal disease by the periodontist. The integrated diagnosis between a periodontist and a stomatologist



Figure 2. Ulcerated and painful lesions at dorsum (A) and lateral edge (B) of the tongue.

led to the diagnosis of an immune-mediated disease presenting DG.

The biopsy to obtain a satisfactory fragment for the diagnosis should preferably be performed in an area close to the lesion (perilesional biopsy). The main histological finding is the formation of the intraepithelial cleft above the basal cell layer that occurs as a result of the autoimmune attack on the desmosomes. The cells of the spinous layer of the surface epithelium are typically separated, that is, in acantholysis, so that they tend to assume a rounded shape, called Tzanck cells. Although affected by acantholysis, the basal keratinocytes remain attached to the basement membrane, producing the characteristic "row of tombstones" pattern[11,13,17].

The differential diagnosis of PV should rely on histopathological and, whenever available, immunofluorescence findings rather than on the clinical appearance alone[2,18]. In PV, the cleft is intraepithelial (suprabasal) and is accompanied by acantholysis, whereas in mucous membrane pemphigoid the separation is subepithelial, with detachment of the full-thickness epithelium from the connective tissue and absence of acantholytic cells[9,18]. Oral lichen planus, in turn, shows a band-like (lichenoid) lymphocytic infiltrate at the epithelium–connective tissue interface with hydropic degeneration of the basal cell layer and without clefting[9]. Recognizing these distinctive features is essential, since a misdiagnosis may expose the patient to ineffective treatment and allow the progression of a potentially life-threatening disease[2,7].

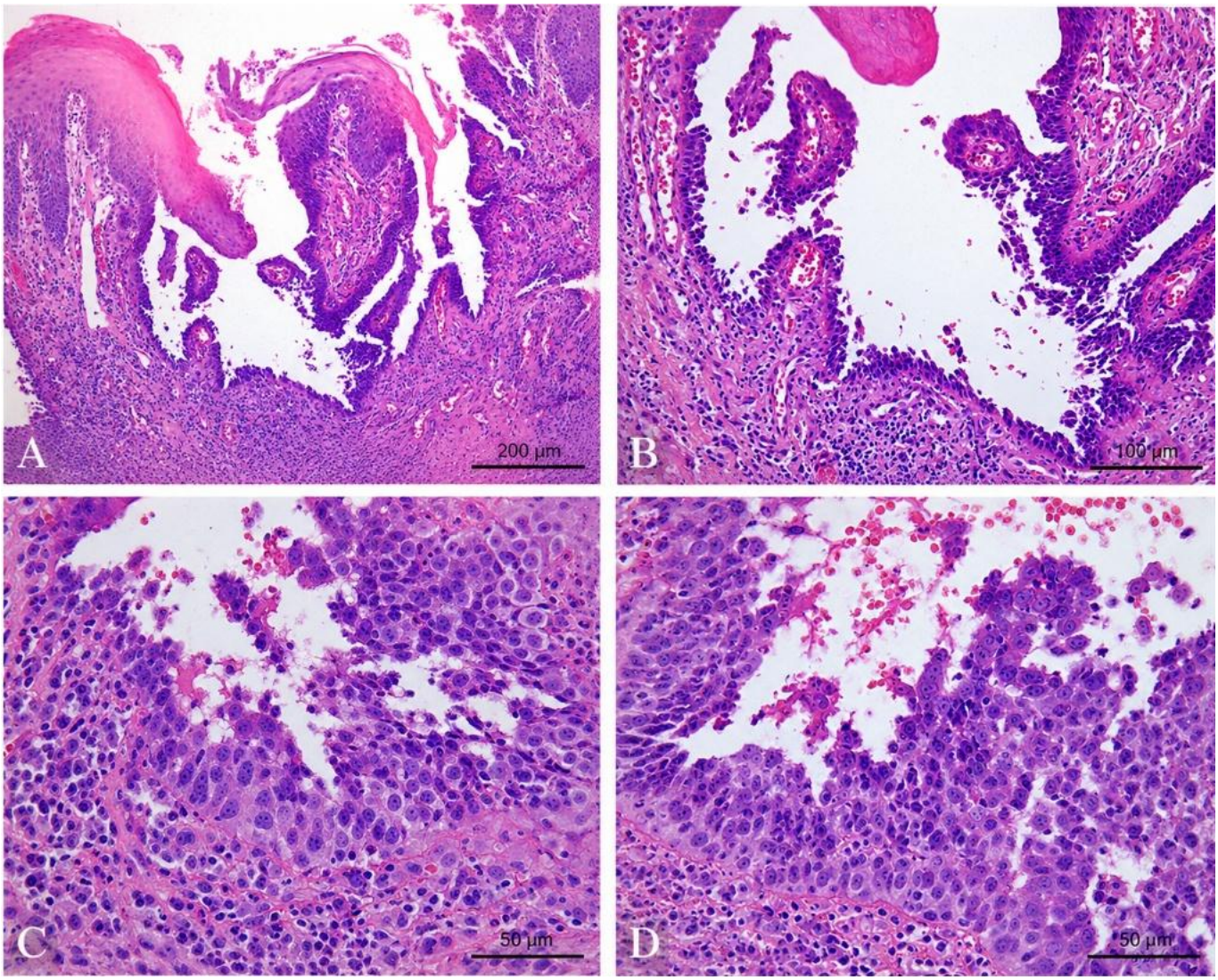

Figure 3. Microscopic aspects of the lesion, showing intraepithelial cleft (A), tombstone appearance of the single-layer epithelial lining (B), and many acantholytic cells (C, D).

Immunofluorescence is an important complementary test for establishing the final diagnosis, but it is expensive and difficult to access for some patients. It is typically requested when there are doubts about the diagnosis based on clinical and morphological findings. In pemphigus vulgaris, direct and indirect immunofluorescence are positive[11].

In addition to traditional diagnostic approaches (histopathological and immunofluorescence examination), the BIOCHIP mosaic and multivariant ELISA are two new serological methods that can be used in the diagnosis of pemphigus. Autoantibodies other than those directed to desmoglein 1 and 3 may be involved in the pathogenesis of PV; therefore, new diagnostic techniques are being investigated and may be recommended in the future. However, the gold standard in the diagnosis of PV is histological analysis and immunofluorescence[17].

In this case, the treatment included periodontal control, which was added to the management of the underlying systemic disease. Systemic corticosteroid therapy is usually necessary, because the lesions are persistent, mainly in the oral cavity. For the systemic treatment of PV, immunosuppressive drugs such as azathioprine, cyclosporine, cyclophosphamide, and immunoglobulins can be combined with corticosteroids in more severe cases[11]. Additionally, secondary infection needs to be evaluated closely, as does dehydration and the risk of death[12,16].

Systemic treatment is challenging, considering both the side effects and the patient's compliance. Immunosuppressive medications may predispose to opportunistic infections, neoplasms, and other systemic complications. In addition, corticosteroid therapy may trigger significant adverse effects, such as hypertension, hyperglycemia, osteoporosis, psychiatric changes, and



Figure 4. Partial remission of lesions 7 days after biopsy and corticosteroid therapy.



Figure 5. Patient after 6 years of follow-up, presenting the oral mucosa (gums and tongue) in normal conditions.

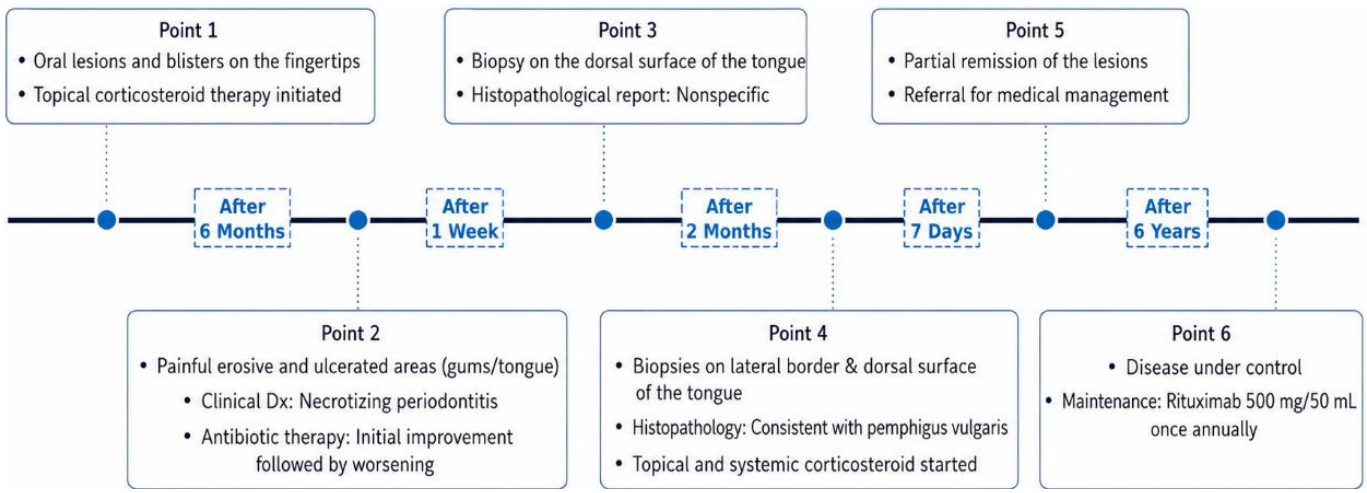

Figure 6. Timeline of the case reported, from onset of symptoms to diagnosis and follow-up.

an increased risk of infections, especially when used long term[12,16].

Biological agents such as rituximab are promising alternatives in the treatment of PV[11,16,19]. Low-dose rituximab has been shown to be a beneficial and safe therapeutic option for patients with moderate to severe PV. Rituximab combined with short-term corticosteroid therapy was safe and significantly more effective than corticosteroid therapy alone, promoting a higher rate of sustained remission and reducing the need for cumulative corticosteroid doses[19].

The strengths of this study include the multidisciplinary approach to both diagnosis and treatment, the emphasis on the risks associated with misdiagnosis, and the role of oral pathologists in achieving an accurate diagnosis. A limitation of the study is that it reports only a single case.

CONCLUSION

This clinical case underscores that thorough knowledge of the clinical and histopathological features of PV is essential for establishing an accurate diagnosis. We emphasize the importance of histopathological evaluation performed by a pathologist specialized in oral lesions, as well as the need for obtaining a representative biopsy specimen. In addition, familiarity with the clinical characteristics of DG, its possible associations with other conditions, and the appropriate therapeutic approaches is fundamental for the correct management of affected patients. Early recognition of immune-mediated diseases should be encouraged among dental professionals, since oral manifestations may represent the first and most persistent clinical signs of conditions such as PV. Finally, the involvement of a multidisciplinary healthcare team is crucial to ensure comprehensive care and to improve the patient's overall clinical outcome.

ACKNOWLEDGMENTS

The authors thank the Diagnostic Center for Oral Diseases (DCOD) for help in diagnosing the case and Dr Caroline Schmalfuss for referring the patient.

AUTHORS' CONTRIBUTIONS

KDS: Conceptualization, Data curation, Formal analysis, Investigation, Methodology, Software, Supervision, Validation, Visualization, Writing – original draft, Writing – review & editing. CLA: Data curation, Formal analysis, Writing – original draft, Writing – review & editing. BMB: Formal analysis, Software, Writing – review & editing. KBJ: Formal analysis, Software, Writing – review & editing. JZC: Data curation, Writing – review & editing.

CONFLICT OF INTEREST STATEMENT

Funding: The authors declare no financial support.
Competing interests: The authors declare no conflicts of interest.
Ethics approval: The patient consented to the use of data for publication
Patients' consent form: The patient consented to the use of data for publication.

DATA AVAILABILITY STATEMENT

The data that support the findings of this study are available from the corresponding author upon reasonable request.

REFERENCES

1. Holmstrup P, Plemons J, Meyle J. Non-plaque-induced gingival diseases. J Periodontol. 2018;89(Suppl 1):S28-S45. https://doi.org/10.1002/JPER.17-0163
2. Scribante A, Pellegrini M, Li Vigni G, Pulicari F, Spadari F. Desquamative gingivitis, oral hygiene, and autoimmune oral diseases: a scoping review. Appl Sci. 2023;13(18):10535. https://doi.org/10.3390/app131810535
3. Hernández-Ríos P, Espinoza I, Salinas M, Rodríguez-Castro F, Baeza M, Hernández M. Distribution of biopsied non plaque-induced gingival lesions in a Chilean population according to the classification of periodontal diseases. BMC Oral Health. 2018;18(1):112. https://doi.org/10.1186/s12903-018-0567-6
4. Shaqman M, Hamdan A, Karadsheh O, Sawair F, Hassona Y. Desquamative gingivitis: a challenging diagnosis for clinicians. Br Dent J. 2020;229(1):26-30. https://doi.org/10.1038/s41415-020-1848-4
5. Maderal AD, Salisbury PL, Jorizzo JL. Desquamative gingivitis: clinical findings and diseases. J Am Acad Dermatol. 2018;78(5):839-48. https://doi.org/10.1016/j.jaad.2017.05.056
6. Mathew M, Nayak VS, Ramaiah SK, Sethuraman S. Desquamative gingivitis: a definite indicator for mucocutaneous disorders. BMJ Case Rep. 2022;15(1):e247857. https://doi.org/10.1136/bcr-2021-247857
7. Daltaban O, Özçentik A, Karaka AA, Üstün K, Hatipo lu M, Uzun S. Clinical presentation and diagnostic delay in pemphigus vulgaris: a prospective study from Turkey. J Oral Pathol Med. 2020;49(7):681-6. https://doi.org/10.1111/jop.13052
8. Garcia-Pola MJ, Rodriguez-López S, Fernández-Vigil A, Bagán L, Garcia-Martín JM. Oral hygiene instructions and professional control as part of the treatment of desquamative gingivitis: a systematic review. Med Oral Patol Oral Cir Bucal. 2019;24(2):e136-e144. https://doi.org/10.4317/medoral.22782

9. Sciuca AM, Toader MP, Stelea CG, Maftei GA, Ciurcanu OE, Stefanescu OM, et al. Desquamative gingivitis in the context of autoimmune bullous dermatoses and lichen planus: challenges in diagnosis and treatment. Diagnostics (Basel). 2022;12(7):1754. https://doi.org/10.3390/diagnostics12071754
10. Kara Polat A, Mülayim MK, Falay Gür T, Acar A, Bozca BC, Ceylan C, et al. Evaluation of the quality of life and the demographic and clinical characteristics of patients with pemphigus with oral mucosal involvement: a multicenter observational study. Dermatol Pract Concept. 2024;14(2):e2024099. https://doi.org/10.5826/dpc.1402a99
11. Saccucci M, Di Carlo G, Bossù M, Giovarruscio F, Salucci A, Polimeni A. Autoimmune diseases and their manifestations in the oral cavity: diagnosis and clinical management. J Immunol Res. 2018;2018:6061825. https://doi.org/10.1155/2018/6061825
12. Kridin K. Pemphigus group: overview, epidemiology, mortality, and comorbidities. Immunol Res. 2018;66(2):255-70. https://doi.org/10.1007/s12026-018-8986-7
13. Sultan AS, Villa A, Saavedra AP, Treister NS, Woo SB. Oral mucous membrane pemphigoid and pemphigus vulgaris: a retrospective two-center cohort study. Oral Dis. 2017;23(4):498-504. https://doi.org/10.1111/odi.12639
14. Dolenc-Voljč M, Povšič K, Kučič AC, Gašperšič R. Pemphigus vulgaris with refractory gingival ulcerations, successfully treated with rituximab: a case report. Clin Case Rep. 2022;10(9):e6321. https://doi.org/10.1002/ccr3.6321
15. Migliari D. Spontaneous resolution of pemphigus vulgaris-induced desquamative gingivitis: a case report and brief review of the literature. Arch Clin Cases. 2025;12(1):1-4. https://doi.org/10.22551/2025.46.1201.10304
16. Cholera M, Chainani-Wu N. Management of pemphigus vulgaris. Adv Ther. 2016;33(6):910-58. https://doi.org/10.1007/s12325-016-0343-4
17. Nili A, Salehi Farid A, Asgari M, Tavakolpour S, Mahmoudi H, Daneshpazhooh M. Current status and prospects for the diagnosis of pemphigus vulgaris. Expert Rev Clin Immunol. 2021;17(8):819-34. https://doi.org/10.1080/1744666X.2021.1945925
18. Suresh L, Neiders ME. Definitive and differential diagnosis of desquamative gingivitis through direct immunofluorescence studies. J Periodontol. 2012;83(10):1270-8. https://doi.org/10.1902/jop.2012.110627
19. Chen DM, Odueyungbo A, Csinady E, Gearhart L, Lehane P, Cheu M, et al. Rituximab is an effective treatment in patients with pemphigus vulgaris and demonstrates a steroid-sparing effect. Br J Dermatol. 2020;182(5):1111-9. https://doi.org/10.1111/bjd.18482