https://doi.org/10.5327/2525-5711.481

J. Oral Diagn 2027;12:e481

Original Article

Morphometric and radiographic assessment of the incisive fossa: thresholds for improving accuracy of diagnosis

Patrícia Maria Fernandes[1], Ivan José Correia-Neto[1], Vinícius Rabelo Torregrossa[1], Isabel Schausltz Pereira Faustino[1], Alan Roger Santos-Silva[1], Ana Cláudia Rossi[2], Felippe Bevilacqua Prado[2], Marcio Ajudarte Lopes[1].

Affiliation:

[1]Department of Oral Diagnosis, Piracicaba Dental School, University of Campinas – UNICAMP-Piracicaba, Brazil.

[2]Department of Morphology, Piracicaba Dental School, University of Campinas – UNICAMP-Piracicaba, Brazil.

Corresponding Author: Márcio Ajudarte Lopes, DDS, MSc, Phd
Oral Diagnosis Department, Piracicaba Dental School, University of Campinas
Address: Av. Limeira, nº 901, Areião, Piracicaba, São Paulo - Brazil
Postal code: 13414- 903
Phone number: +55 19 2106-5320 / 2106-5200
E-mail: malolopes@fop.unicamp.br

ORCIDS:

Patrícia Maria Fernandes — ORCID: 0000-0003-1714-4505
Ivan José Correia-Neto — ORCID: 0009-0007-3828-0107
Vinícius Rabelo Torregrossa — ORCID: 0000-0003-3736-4433
Isabel Schausltz Pereira Faustino — ORCID: 0000-0002-7542-476X
Alan Roger Santos-Silva — ORCID: 0000-0003-2040-6617
Ana Cláudia Rossi — ORCID: 0000-0002-8718-4898
Felippe Bevilacqua Prado — ORCID: 0000-0001-5636-6915
Marcio Ajudarte Lopes — ORCID: 0000-0001-6677-0065

Received: April 29, 2026 - Accepted: November 08, 2026.

In Press

Abstract

Objectives: This study aimed to determine radiographic measurements of the incisive fossa and to establish thresholds that distinguish normal anatomical variations from possible nasopalatine duct cysts. A morphometric evaluation was carried out using dry human skulls, maxillary occlusal radiographs, and cone beam computed tomography. **Methods:** Sixty-six dry human skulls were examined through direct measurements and occlusal radiographs. Cone beam computed tomography was performed when the width of the incisive fossa was six millimeters or greater. Width and length values obtained through the three techniques were compared using the Tukey–Kramer test, considering a significance level of p less than 0.05. **Results:** The mean width and length of the incisive fossa were 5.18 millimeters and 8.22 millimeters in dry skulls, 5.05 millimeters and 9.23 millimeters in occlusal radiographs, and
6.00 millimeters and 6.66 millimeters in cone beam computed tomography. Width values did not differ significantly between dry skulls and radiographs, while length values showed significant differences. Maxillary occlusal radiographs produced reliable width estimates and should be used as the imaging method. **Conclusions:** The width of the incisive fossa is a critical parameter for distinguishing normal anatomical variations from possible nasopalatine duct cysts. Radiolucent areas measuring 6 mm or less in width represent normal anatomical variations, whereas widths between 6 and 10 mm require further evaluation, and widths greater than 10 mm suggest nasopalatine duct cysts.

Keywords: Incisive fossa; Nasopalatine duct cyst; Occlusal radiography; Cone-beam computed tomography.

In Press

Statement of Clinical Significance

Radiolucent areas in the anterior maxilla are frequently encountered in clinical practice and may represent either normal anatomical variations of the incisive fossa or nasopalatine duct cysts. Misinterpretation of these findings can lead to unnecessary surgical interventions. This study provides practical radiographic thresholds to aid in the differentiation between normal anatomy and pathological conditions, highlighting the reliability of maxillary occlusal radiographs for initial assessment and the complementary role of cone-beam computed tomography in borderline cases. These findings support more accurate diagnosis and improved clinical decision-making.

INTRODUCTION

The incisive fossa is a funnel-shaped depression located at the midline of the anterior palate, from which the incisive canals emerge[1,2]. On maxillary occlusal radiographs (MOR), it typically appears as a small, oval or circular radiolucent area, usually measuring up to 6 millimeters. Anatomical variations, such as an enlarged incisive fossa, may mimic a small nasopalatine duct cyst (NDC), creating a diagnostic challenge[3-6].

NDCs are non-odontogenic lesions that may develop along the entire length of the nasopalatine canal, including the incisive fossa region[6,7]. They are often asymptomatic and are frequently discovered incidentally on routine radiographs[3,8-10]. Radiographically, these cysts usually measure 10 to 20 millimeters, although distortions on imaging may misrepresent their actual size[9,11].

In borderline cases, it is difficult to differentiate an enlarged incisive fossa from a small NDC. A radiolucent image around 6 mm in an asymptomatic patient represents a diagnostic challenge. Misinterpreting an NDC as a normal anatomical variation may delay diagnosis and allow the lesion to enlarge, potentially resulting in cortical expansion and involvement of adjacent anatomical structures[11-13]. Conversely, misclassifying a normal anatomical variation as a cyst may lead to unnecessary surgical intervention. Surgical treatment of NDCs may be

In Press

associated with postoperative complications, including hemorrhage, hematoma, infection, and sensory disturbances such as paresthesia[13-15]. In such cases, a correct diagnosis is essential to avoid unnecessary surgical interventions and delayed diagnosis[6,9,10]. Therefore, establishing reliable morphometric thresholds is important to support clinical decision-making and help minimize both unnecessary surgical interventions and delays in the diagnosis of pathological lesions.

Previous studies using cone beam computed tomography (CBCT) have investigated the morphology and dimensions of the nasopalatine canal in different populations, demonstrating anatomical variability across individuals[16-19]. CBCT-based investigations have also explored morphological parameters that may help differentiate NDCs from the normal nasopalatine canal and have examined the relationship between cyst dimensions, clinical symptoms, and postoperative complications[13,14]. These findings highlight the importance of considering anatomical diversity in clinical practice and support the role of CBCT as a complementary diagnostic tool when conventional radiographic findings are inconclusive[15,17]. Nevertheless, further evidence is needed to establish reliable morphometric reference values for the incisive fossa and clarify the role of conventional radiographic measurements in distinguishing normal anatomical variations from findings suggestive of NDCs. Accordingly, this study aimed to determine radiographic measurements of the incisive fossa and to establish thresholds that distinguish normal anatomical variations from possible NDCs.

In Press

MATERIALS AND METHODS

Sample Selection

This study was approved by the Piracicaba Dental School/University of Campinas Ethics Committee (Protocol 125/2015). Ninety-three dry human skulls (HDS) were selected from the Anatomy Area of Piracicaba Dental School/University of Campinas. Skulls presenting malformations, fractures or defects around the incisive fossa area were excluded. After applying exclusion criteria, the final sample consisted of 66 HDS. No sample size calculation was performed, as this was a convenience sample.

Study Design

The HDS were submitted to linear measurements using a digital caliper followed by an assessment at MOR. For cases with an incisive fossa mesiodistal width ≥ 6 mm on MOR, which was used as a cut-off point based on previous literature indicating the threshold for potential cystic lesions[3,20], CBCT was performed, and the same linear measurements were reassessed (Figure 1).

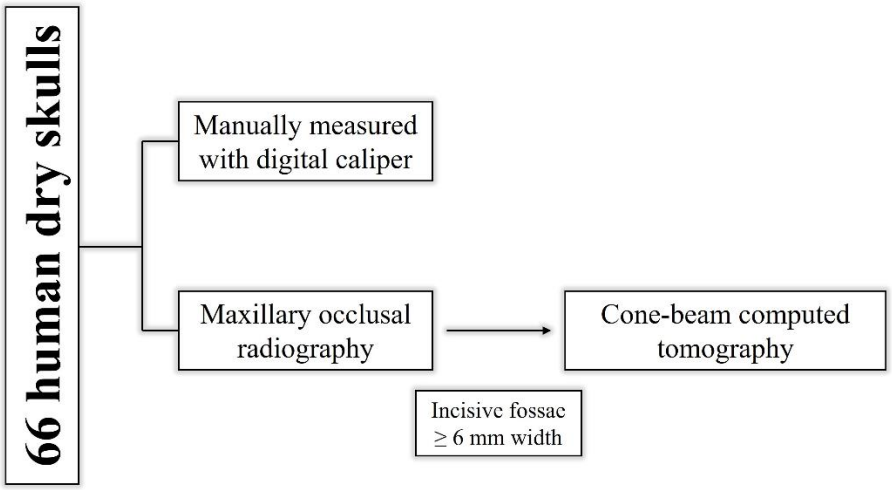

Figure 1. Flowchart of the study design. A total of 66 HDS were measured with a digital caliper and submitted to MOR. Cases with incisive fossae ≥6 mm in width were further evaluated using CBCT.

Examiners

All the linear measurements, both in the HDS as well as in the MOR and in the CBCT, were performed by two previously calibrated examiners. Each measurement was performed twice, by the same examiner, considering a minimum interval of seven days between evaluations. All measurements were obtained under standardized conditions and at different moments to ensure reliability.

Measurement Parameters

- Human Dry Skulls

Mesiodistal width and anteroposterior length was measured directly on HDS using a digital caliper (Starrett – Série 727, Indústria e Comércio Ltda, Itu, São Paulo, Brasil). Measurements were obtained between the most external limits of the incisive fossa, using anatomical landmarks as reference points.

- Maxillary Occlusal Radiographs

To perform MOR, the HDS were stabilized using a wooden wedge positioned below the occipital bone. Radiographic equipment (Sommo Wall-Mounted Pantographic Unit, GNATUS Medical-Dental Equipment Ltd., Ribeirão Preto, São Paulo, Brazil) with a power of 70kVp and 7mA was used, as well as Insight Radiographic Films (IO-41, Occlusal, Kodak, NY, USA) measuring 5.7 x 7.6 cm. An occlusal positioner (FPX, Prisma Instrumentos Odontológicos, Pirituba, São Paulo, Brasil) was also used. An exposure time of 0.32 seconds was performed. The distance from X-ray source to X-ray film was 40 cm, using a horizontal angle of 0º and a vertical angle of 65º, according to the occlusal positioner. The processing stage was performed by an automatic processor (Gendex GXP, Gendex Dental System, Hatfield, Pennsylvania, USA). The radiographic films were scanned using an optical scanner with a transparency reader (HP ScanJet G4050, Hewlett-Packard Company®, Washington, USA) with a resolution of 300 dpi, respecting their original size. Scanned images were archived and analyzed in a personal computer in a dimmed room, with ambient light conditions, at a 30 cm distance from the

In Press

computer screen by both examiners, in the same conditions but in different moments.

For linear measurement evaluation, the scanned images were submitted to Image-J-Link Program (http://rsbweb.nih.gov/ij/index.html). Mesiodistal width and anteroposterior length were measured using an electronic ruler tool.

- Cone-Beam Computed Tomography of the Maxilla

CBCT images were obtained using a Sirona Dental Systems® equipment (Bensheim, Germany) with voxel size of 0.125 mm, field of view of 6x6 cm and exposure dose of 6 mGy. CBCT was performed only in those cases that presented an incisive fossa mesiodistal width ≥ 6 mm on MOR. Thirteen cases underwent CBCT and the axial section has been used to evaluate the anterior maxilla. To perform the linear measurements on the CBCT images, the lowest axial section, in other words, the one closest to the palate was selected so that the incisive fossa outlines were well-defined. Linear measurements concerning the incisive fossae mesiodistal width and anteroposterior length were all measured by both examiners, under the same conditions but different moments, using an electronic ruler tool available in Tomographic Software (Galaxis Galileos Sidexis – Sirona Dental Systems®, Charlotte, NC, USA).

Statistical Analysis

Data corresponding to mean values ± standard deviation of three replicates of width and length dimensions were calculated. Intrarater and interrater reliability were verified by the Intraclass Correlation Coefficient (ICC) and by Kappa test, respectively. All measurements made directly on HDS were statistically compared with those obtained from the scanned images of MOR and CBCT using the Tukey-Kramer test. The level of significance was 5% ($p \leq 0.05$).

RESULTS

Demographic Profile

Sixty-six HDS fulfilled our inclusion criteria. All skulls belonged to adult Brazilians, with an estimated age at death ranging from 20 to 70 years. The including 38 males (57.6%),

In Press

25 females (37.8%) and in 3 cases (4.6%) sex was not available. Fifty were edentulous (75.8%), 15 were partially edentulous (22.7%) and 1 (1.5%) had complete dentition.

In Press

Dry Skulls

The measurements performed directly on incisive fossae of HDS revealed a mean value of 5.18 mm in width and 8.22 mm in length. Regarding width, 57 cases (86%) measured less than 6 mm, 8 of them (12%) ranged between 6 to 10 mm, and 1 (1.5%) measures more than 10 mm. Concerning the length, 20 cases (30%) measured less than 6 mm, 31 (47%) ranged between 6 to 10 mm, and 15 (23%) measured more than 10 mm. The largest incisive fossa presented 12.4 mm in width and 15.7 mm in length. The smallest one presented 2.2 mm in width and 2.9 mm in length (Table 1).

Maxillary Occlusal Radiographs

The mean width and length of the incisive fossae measured on MOR images were 5.05 mm and 9.23 mm, respectively. Regarding width, 57 cases (86%) measured less than 6 mm, 7 (11%) showed measurements between 6 to 10 mm and 2 (3%) showed measurements above 10 mm. Concerning the length, 9 cases (14%) showed measurements less than 6 mm, 35 (53%) between 6 to 10 mm, and 22 (33%) measured more than 10 mm. The largest incisive fossa presented 13.3 mm in width and 18.7 mm in length. The smallest one presented 2.5 mm in width and 2.2 mm in length (Table 1).

Comparison between the human dry skulls and the maxillary occlusal radiography

The incisive fossae width measurements were very similar between the HDS and MOR images ($p=0.1046$). In contrast, length measurements in HDS were lower than those obtained from MOR images ($p = 0.005$). This confirms that MOR reliably reproduces fossa width but tends to overestimate length. These findings suggest that MOR provides comparable estimates of incisive fossa width but may yield greater length measurements than direct measurements of dry skulls.

In Press

Table 1. Dimensions (in mm) of incisive fossae on human dry skull, occlusal radiography and cone-beam computed tomography.

Measurements	n	Mean	Minimum	Maximum	SD	CI (95%)	ICC Examiner 1	ICC Examiner 2	Kappa
Dry skull	66								
Width		5.18	2.23	12.46	1.44	5.01- 5.36	0.94	0.94	0.88
Length		8.22	2.93	15.72	2.69	7.9 - 8.54	0.96	0.91	0.95
Occlusal radiography	66								
Width		5.05	2.5	13.30	1.75	4.84 - 5.25	0.88	0.96	0.94
Length		9.23	2.22	18.69	3.33	8.84 - 9.63	0.7	0.68	0.86
CBCT	13								
Width		6.00	3.15	11.40	2.26	5.36 - 6.65	0.99	0.99	0.99
Length		6.66	4.08	12.01	2.10	6.06 -7.26	0.97	0.98	0.99

SD= Standard deviation; CI= Confidence interval; ICC= Intraclass correlation coefficient

In Press

Across HDS and MOR measurements, most incisive fossae had widths below 6 mm. A smaller proportion presented widths between 6 and 10 mm, while only one HDS measurement and two MOR measurements exceeded 10 mm. These findings describe the morphometric distribution of the incisive fossae in the present sample; however, the measurements alone do not establish the presence of NDCs.

Cone-Beam Computed Tomography

Only HDS presenting an incisive fossa width of ≥6 mm on MOR underwent CBCT. The mean width and length of the incisive fossae on CBCT were 6.00 mm and 6.66 mm, respectively. Six cases (46.2%) had a width of <6 mm, five (38.5%) had a width of 6–10 mm, and two (15.4%) had a width of >10 mm. Regarding length, seven HDS (53.8%) had measurements of <6 mm, four (30.8%) had measurements of 6–10 mm, and two (15.4%) had measurements of >10 mm. The maximum width and length were 11.40 mm and 12.01 mm, respectively, whereas the minimum width and length were 3.15 mm and 4.08 mm, respectively (Table 1).

Figures 2A and 2B show a normal incisive fossa in a dry skull and its corresponding radiographic and tomographic images, whereas Figure 2C shows an enlarged incisive fossa. Figures 3A and 3B illustrate a borderline incisive fossa measuring 6.1 mm in width and 7.3 mm in length. Direct measurements using a digital caliper are shown in Figure 4. Figure 4A illustrates a normal incisive fossa measured in the coronal plane, whereas Figure 4B shows an enlarged fossa measuring 11.1 × 11.5 mm. Figure 4C shows a caliper reading of 13.29 mm.

In Press



Figure 2. Direct measurement of the incisive fossa in HDS using a digital caliper. The images illustrate the direct assessment of incisive fossa dimensions. (C) Digital caliper showing a measurement of 13.29 mm.

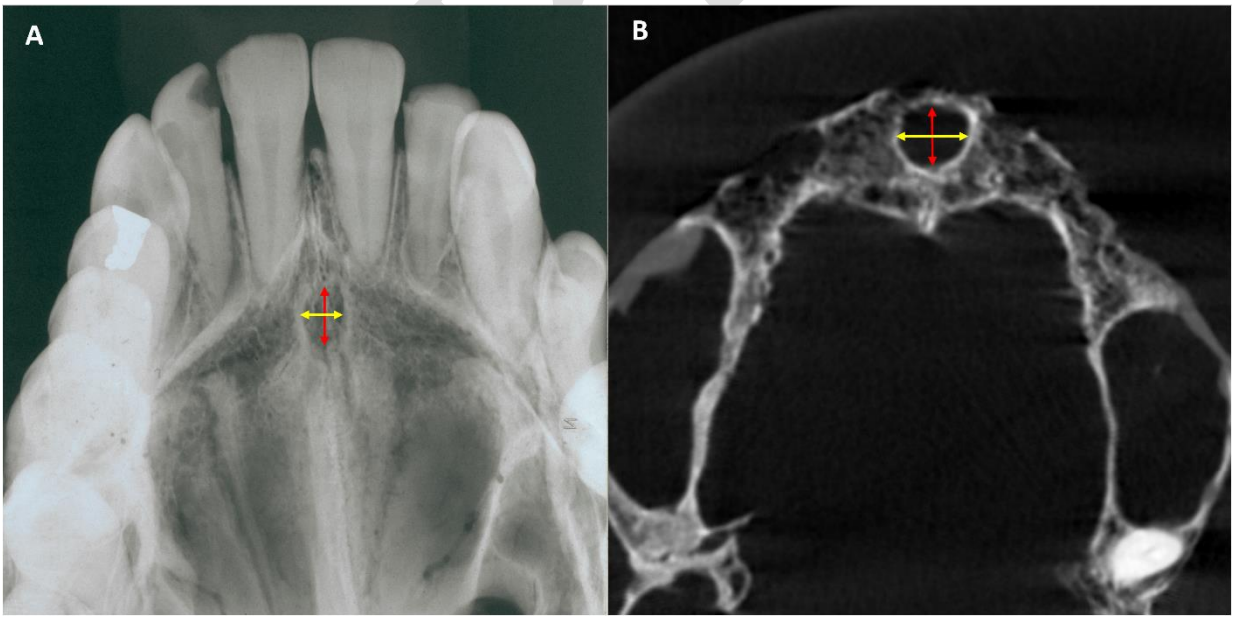

Figure 3. A borderline incisive fossa, measuring 6.1 mm in width and 7.3 mm in length on a dry skull and its corresponding radiographic and tomographic images, is compatible with an enlarged fossa (A-B).

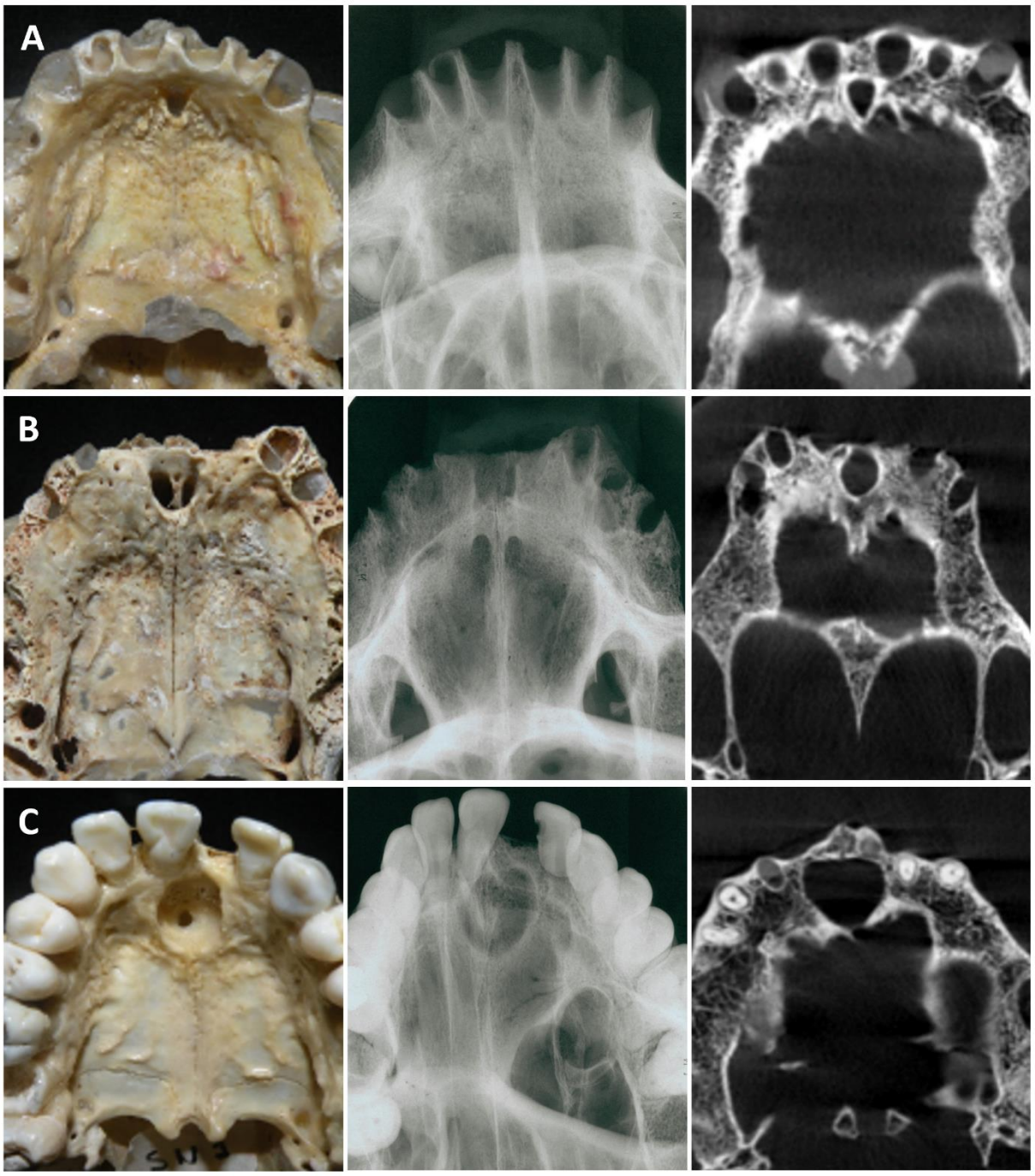

Figure 4. Radiographic and tomographic assessment of the incisive fossae in HDS. The figure presents images of the incisive fossae obtained from direct examination of the skulls, MOR, and CBCT.

DISCUSSION

Previous studies have reported incisive fossa width values of approximately 3–5 mm and length values of approximately 3–4 mm. In the present study, the mean width (5.18 mm) was similar to previously reported values, whereas the mean length (8.22 mm) was greater. However, our examiners demonstrated good agreement in length measurements ($\kappa = 0.95$). Chamda and Shear reported more similar length measurements, with a mean of 10.19 mm in HDS from a sample consisting exclusively of individuals of African descent[3]. This population may present larger incisive fossa dimensions. Unfortunately, ethnic information was not available for the HDS in our sample, so it is unknown whether ethnicity explains the greater mean length observed. Differences in anatomical landmarks, measurement protocols, and population characteristics may also contribute to the variation between studies.

In the present study, width measurements obtained from HDS and MOR images were similar ($p = 0.1046$). In contrast, length measurements obtained from HDS were lower than those obtained from MOR images ($p = 0.005$). This discrepancy may reflect the difficulty of identifying the anterior border of the incisive fossa on two-dimensional radiographs, as well as the effects of radiographic projection, including angulation, magnification, distortion, and superimposition of adjacent anatomical structures. Factors such as overlap with the anterior nasal spine, the presence of dental alveoli, and shallow fossae may also have contributed to the measurement differences. Therefore, although MOR may provide width measurements comparable to direct measurements of dry skulls, radiographic length measurements should be interpreted cautiously because they may be affected by projection geometry.

Despite the limitations of length measurements, width values may help identify cases that warrant further investigation. However, the 6-mm threshold used in this study should be interpreted as a screening criterion rather than a definitive distinction between normal anatomy and NDC. Radiographs are relatively inexpensive, involve comparatively low radiation exposure, and are widely available. In borderline cases, particularly when measurements on MOR images are close to 6 mm, CBCT may provide additional information by delineating

In Press

anatomical boundaries, revealing anatomical features, and clarifying relationships with adjacent structures[13]. CBCT may therefore be considered a complementary examination when conventional radiographs are inconclusive and additional anatomical information is needed for diagnosis or clinical management[12,20]. The suitability of this approach should be interpreted in light of the findings and limitations of the present study.

CBCT studies have demonstrated considerable morphological variability in the nasopalatine canal across individuals and populations. Beshtawi et al. highlighted population-related differences in canal morphology[16], while Janovic et al. demonstrated the value of CBCT in differentiating normal anatomy from potential NDC in borderline cases[20]. Rai et al. reported associations between certain morphometric parameters, age, and sex[17]. Aydin and Gaş described anatomical differences in pediatric and adolescent patients[18], while Linjawi et al. reported sex-related differences in canal length[19]. More specifically, Chatzipetros et al. evaluated 124 CBCT examinations and found that the diameter of the incisive foramen generally increased with age. They also reported greater mean dimensions of the nasopalatine canal and adjacent buccal osseous plate in males than in females, while edentulous individuals showed reduced dimensions of the adjacent buccal osseous plate[21]. Demiralp et al. investigated the anatomical and volumetric characteristics of the nasopalatine canal in 200 CBCT examinations and found that canal volume increased with age in the anterior edentulous group and was greater in males. Their findings also indicated associations between premaxillary resorption and the anatomical dimensions of the incisive and nasal foramina and the residual buccal bone[22]. These findings indicate that age, sex, and dental status may contribute to anatomical variability and should be considered when interpreting incisive fossa measurements.

In the present study, the estimated age at death of the HDS ranged from 20 to 70 years, but individual age data were unavailable. Consequently, we could not determine whether age was associated with incisive fossa dimensions or whether the skulls with measurements suggestive of NDC belonged to older individuals. Similarly, the available records did not provide sufficient information to investigate sex-related differences or the duration of edentulism in these specific skulls. Although previous studies have identified associations

In Press

between age, sex, and dental status and aspects of nasopalatine canal morphology, the lack of individual demographic information and the limited CBCT sample in the present study precluded a reliable assessment of these associations. These variables should therefore be considered potential sources of anatomical variation rather than explanations established by our findings.

Our findings highlight the potential role of CBCT as a complementary examination when conventional radiographs are inconclusive. In addition, previous morphometric studies have demonstrated considerable variability in nasopalatine canal dimensions across populations, emphasizing the importance of considering anatomical variation when interpreting measurements[16-20]. However, the clinical applicability of the 6-mm threshold proposed in the present study requires further validation. A correct diagnosis of NDC requires a thorough assessment of radiographic dimensions and features, clinical signs and symptoms when present, and histopathological confirmation. In this study, cases suggestive of NDC were identified based on their measurements and anatomical features. Two HDS with potential cystic lesions were identified, corresponding to approximately 3% of the sample. This percentage represents the proportion of skulls with suspicious findings in the examined sample and should not be interpreted as the prevalence of NDC in the general population, particularly because the lesions were not histopathologically confirmed**.** Both cases presented width and length measurements greater than 1 cm. Four additional HDS were classified as borderline cases, with measurements around 6 mm, although they displayed cyst-like radiographic features, including rounded radiolucent areas with well-defined borders on MOR and CBCT images.

NDC is described as the most common non-odontogenic cyst of the maxilla. In a retrospective series of 334 cases, Swanson et al. reported a mean age at diagnosis of 42.5 years, a slight male predominance, and a mean radiographic diameter of 17.1 mm[23]. These epidemiological findings provide context for interpreting the suspicious cases identified in the present study; however, direct comparison is not possible because the age and sex of the affected skulls were unavailable and the lesions were not histopathologically confirmed. Previous studies of histopathologically confirmed NDC have reported that many lesions exceed 1 cm in

In Press

diameter[5,6,23]. Swanson et al. found that approximately one-third of the cases measured more than 1 cm, although smaller lesions were also documented, including some measuring 6 mm or less[21]. Therefore, lesion size alone cannot reliably distinguish an NDC from normal incisive canal anatomy, and the two cases identified in the present study should be described as suggestive of potential cystic lesions rather than confirmed NDC.

This study has several limitations related to the characteristics of the dry-skull sample and the imaging methods. Although the estimated age at death ranged from 20 to 70 years, individual age data were unavailable, preventing analysis of the relationship between age and incisive fossa dimensions. The high proportion of edentulous skulls may indicate a sampling bias toward older individuals, although this could not be confirmed. Furthermore, the available records did not allow differentiation between antemortem and postmortem tooth loss or determination of the duration of edentulism. Sex and other demographic characteristics were also unavailable, precluding assessment of their potential influence on the measurements.

CBCT was performed only in HDS whose MOR measurements met the study's selection criterion, resulting in a small, selected subsample that may not represent the entire skull collection. In addition, MOR measurements may have been affected by projection geometry, angulation, magnification, distortion, and anatomical superimposition. Finally, the lesions considered suggestive of NDC were not histopathologically confirmed; therefore, the findings do not establish the diagnostic accuracy of MOR or CBCT for NDC. Future studies involving larger samples, documented demographic and dental characteristics, standardized measurement protocols, and histopathological confirmation where available are needed to validate the proposed threshold and assess its diagnostic performance.

CONCLUSION

This study established preliminary reference thresholds for the radiographic assessment of the incisive fossa. Maxillary occlusal radiographs reliably reproduced width measurements, while cone-beam computed tomography provided complementary information in borderline cases. Based on our findings, radiolucent areas with a width of up to 6 mm may represent normal

In Press

anatomical variations, whereas those with a width greater than 6 mm and up to 10 mm warrant further evaluation with cone-beam computed tomography. Radiolucent areas with a width greater than 10 mm may raise strong suspicion of a nasopalatine duct cyst. These thresholds may assist clinicians in interpreting incisive fossa dimensions and guiding further evaluation.

Authors contributions

Conceptualization: P.M.F., M.A.L.

Methodology: P.M.F., M.A.L.

Collection and assembly of data: P.M.F.

Data analysis and interpretation: P.M.F., I.J.C.N., V.R.T., I.S.P.F., A.C.R., F.B.P., M.A.L.

Manuscript writing: P.M.G., I.J.C.N.

Supervision: A.R.S.S., M.A.L.

Final approval of manuscript: All authors.

Acknowledgement

We acknowledge the support of the Coordination for the Improvement of Higher Education Personnel – Brazil (CAPES – Finance Code 001) for this study.

Conflict of interest

We declare that the authors have no financial relationship with any commercial associations, current and within the past five years, that might pose a potential, perceived or real conflict of interest. These include grants, patent-licensing arrangements, consultancies, stock or other equity ownership, advisory board memberships, or payments for conducting or publicizing our study.

Ethical Approval

This study was approved by the Ethics Committee of the Piracicaba Dental School/University of Campinas (Protocol 125/2015).

Funding

This study was financed by the Coordination for the Improvement of Higher Education Personnel (CAPES – Finance Code 001). ARSS, and MAL are research fellows funded by the National Council for Scientific and Technological Development (CNPq).

In Press

REFERENCES

1. Anneroth G, Hall G, Stuge U. Nasopalatine duct cyst. Int J Oral Maxillofac Surg. 1986 Oct;15(5):572-80. doi: 10.1016/s0300-9785(86)80061-8.
2. Bodin I, Isacsson G, Julin P. Cysts of the nasopalatine duct. Int J Oral Maxillofac Surg. 1986 Dec;15(6):696-706. doi: 10.1016/s0300-9785(86)80110-7.
3. Chamda RA, Shear M. Dimensions of incisive fossae on dry skulls and radiographs. Int J Oral Surg. 1980 Dec;9(6):452-7. doi: 10.1016/s0300-9785(80)80075-5.
4. Dedhia P, Dedhia S, Dhokar A, Desai A. Nasopalatine duct cyst. Case Rep Dent. 2013;2013:869516. doi: 10.1155/2013/869516.
5. Barros CCDS, Santos HBP, Cavalcante IL, Rolim LSA, Pinto LP, et al. Clinical and histopathological features of nasopalatine duct cyst: A 47-year retrospective study and review of current concepts. J Craniomaxillofac Surg. 2018 Feb;46(2):264-268. doi: 10.1016/j.jcms.2017.11.014.
6. Escoda Francolí J, Almendros Marqués N, Berini Aytés L, Gay Escoda C. Nasopalatine duct cyst: report of 22 cases and review of the literature. Med Oral Patol Oral Cir Bucal. 2008 Jul 1;13(7):E438-43.
7. Etoz M, Sisman Y. Evaluation of the nasopalatine canal and variations with cone-beam computed tomography. Surg Radiol Anat. 2014 Oct;36(8):805-12. doi: 10.1007/s00276-014-1259-9.
8. Falci SG, Verli FD, Consolaro A, et al. Morphological characterization of the nasopalatine region in human fetuses and its association to pathologies. J Appl Oral Sci. 2013;21(3):250-5.
9. Hopper-Hall, H. Cyst of developmental origin in the premaxillary region with special reference to their diagnosis. Br Denta J. 1938;65:405–434.
10. Nonaka CF, Henriques AC, de Matos FR, de Souza LB, Pinto LP. Nonodontogenic cysts of the oral and maxillofacial region: demographic profile in a Brazilian population over a 40-year period. Eur Arch Otorhinolaryngol. 2011 Jun;268(6):917-22. doi: 10.1007/s00405-010-1458-x
11. Perumal CJ. An unusually large destructive nasopalatine duct cyst: a case report. J Maxillofac Oral Surg. 2013 Mar;12(1):100-4. doi: 10.1007/s12663-011-0201-5.
12. Schiff BS, Kringstein G, Stoopack JC. An extremely large and facially distorting nasopalatine duct cyst. Oral Surg Oral Med Oral Pathol. 1969;27(5):590-594. https://doi.org/10.1016/0030-4220(69)90088-7.

In Press

13. Suter VG, Sendi P, Reichart PA, Bornstein MM. The nasopalatine duct cyst: an analysis of the relation between clinical symptoms, cyst dimensions, and involvement of neighboring anatomical structures using cone beam computed tomography. J Oral Maxillofac Surg. 2011 Oct;69(10):2595-603. doi: 10.1016/j.joms.2010.11.032.
14. Suter VG, Warnakulasuriya S, Reichart PA, Bornstein MM. Radiographic volume analysis as a novel tool to determine nasopalatine duct cyst dimensions and its association with presenting symptoms and postoperative complications. Clin Oral Investig. 2015 Sep;19(7):1611-8. doi: 10.1007/s00784-014-1391-2.
15. Sane VD, Gadre KS, Halli R, Singh V, Doshi P, Saddiwal R, et al. Role of cone-beam computed tomography in diagnosis and management of nasopalatine duct cyst. J Craniofac Surg. 2014 Jan;25(1):e92-4. doi: 10.1097/SCS.0000000000000427.
16. Beshtawi KR. Morphology and dimensions of the nasopalatine canal in Palestinian patients assessed using cone beam computed tomography. Sci Rep. 2025 Apr 17;15(1):13248. doi: 10.1038/s41598-025-97392-7.
17. Rai S, Misra D, Misra A, Khatri M, Kidwai S, et al. Significance of Morphometric and Anatomic Variations of Nasopalatine Canal on Cone-Beam Computed Tomography in Anterior Functional Zone - A Retrospective Study. Ann Maxillofac Surg. 2021 Jan-Jun;11(1):108-114. doi: 10.4103/ams.ams_283_20.
18. Aydin KC, Gaş S. Anatomical and Morphological Assessment of Nasopalatine Canal in Pediatric and Adolescent Population via Cone Beam Computed Tomography. J Craniofac Surg. 2021 Sep 1;32(6):1994-1998. doi: 10.1097/SCS.0000000000007476.
19. Linjawi AI, Othman MA, Dirham AA, Ghoneim SH, Aljohani SR, Dause RR, et al. Morphological evaluation of the incisive canal with reference to gender and age: A cone-beam computed tomography study. Niger J Clin Pract. 2021 Nov;24(11):1596-1601. doi: 10.4103/njcp.njcp_40_21.
20. Janovic A, Bracanovic D, Antic S, Markovic-Vasiljkovic B. Morphological CBCT parameters for an accurate differentiation between nasopalatine duct cyst and the normal nasopalatine canal. Head Face Med. 2024 Sep 28;20(1):54. doi: 10.1186/s13005-024-00458-6.
21. Chatzipetros E, Tsiklakis K, Donta C, Damaskos S, Angelopoulos C. Morphological Assessment of Nasopalatine Canal Using Cone Beam Computed Tomography: A Retrospective Study of 124 Consecutive Patients. Diagnostics (Basel). 2023 May 18;13(10):1787. doi: 10.3390/diagnostics13101787.

In Press

22. Demiralp KÖ, Kurşun-Çakmak EŞ, Bayrak S, Sahin O, Atakan C, Orhan K. Evaluation of Anatomical and Volumetric Characteristics of the Nasopalatine Canal in Anterior Dentate and Edentulous Individuals: A CBCT Study. Implant Dent. 2018 Aug;27(4):474-479. doi: 10.1097/ID.0000000000000794.
23. Swanson KS, Kaugars GE, Gunsolley JC. Nasopalatine duct cyst: an analysis of 334 cases. J Oral Maxillofac Surg. 1991 Mar;49(3):268-71. doi: 10.1016/0278-2391(91)90217-a.

In Press