J. Oral Diagn 2026;11:e516
https://doi.org/10.5327/2525-5711.516

ORIGINAL ARTICLE

Association between mandibular lesion size and mandibular bone quality index

Nazgol Ravanbakhsh[1]*, Binali Çakır[1], Gamze Nur Bayramoğlu[1]

Abstract:

Objective: The present study aimed to evaluate the association between the size of mandibular lesions and mandibular bone quality using the Bone Quality Index (BQI) based on cone-beam computed tomography (CBCT) images. Methods: This retrospective radiographic study evaluated CBCT images. A total of 49 histopathologically confirmed mandibular lesions were included. Mandibular bone quality was assessed using BQI on cross-sectional sections, while lesion size was measured on panoramic reconstruction images. Statistical analyses were performed to investigate associations between lesion dimensions and bone-quality characteristics. Results: No statistically significant association was found between lesion size and BQI ($p>0.05$). Findings regarding other variables were interpreted as exploratory. Conclusions: Within the limitations of this retrospective study, no definitive association was observed between the size of mandibular lesions and mandibular bone quality assessed by BQI. The findings indicate that BQI primarily reflects local osseous characteristics rather than serving as a direct determinant of lesion size. Further prospective studies with larger, homogeneous cohorts are needed to better understand these local dynamics.

Keywords: Cone-beam computed tomography; Mandible; Bone quality; Bone quality index; Central jaw lesions.

INTRODUCTION

The mandible is a dynamic structure influenced by both local and systemic factors and serves as an important indicator in the assessment of an individual's overall bone health. Bone quality is defined by parameters such as cortical thickness, trabecular density, and bone architecture, and plays a decisive role in clinical decision-making processes. Pathological processes affecting the mandible may vary depending on numerous factors, including age, sex, hormonal status, nutritional habits, systemic bone metabolism disorders such as osteoporosis, diabetes mellitus, endocrine diseases, and long-term medication use. These factors may lead to radiographic changes in the mandible, including cortical thinning, decreased trabecular density, and irregularities in bone architecture[1].

Local factors include odontogenic infections, periodontal diseases, trauma, surgical procedures, edentulism, functional alterations, as well as cystic and neoplastic lesions affecting the jaw. These local pathological processes may result in structural changes in the mandibular bone, such as resorption, expansion, and alterations in trabecular organization. In particular, lesions such as radicular cysts, dentigerous cysts, odontogenic keratocysts, ameloblastomas, and other odontogenic tumors may produce radiolucent or mixed radiographic changes in the mandible. The biological behavior and growth potential of these lesions are closely related to their histopathological characteristics and interactions with the surrounding tissues[2].

With advances in imaging technologies, the use of cone-beam computed tomography (CBCT) has become increasingly widespread in the evaluation of the maxillofacial skeleton in addition to panoramic radiography. Compared with panoramic radiography, CBCT

Statement of Clinical Significance
Assessment of mandibular bone quality in patients with mandibular lesions using CBCT may provide additional information for treatment planning and patient management. The findings of this study contribute to understanding the relationship between lesion size and mandibular bone quality.

[1]Atatürk University, Faculty of Dentistry, Department of Oral and Maxillofacial Radiology – Erzurum, Turkey.
***Correspondence to:** E-mail: nazgolrnb@gmail.com
Received on July 11, 2026. Accepted on August 30, 2026.
https://doi.org/10.5327/2525-5711.516

CC BY

reduces superimposition and distortion, allowing a more accurate and detailed assessment of bone morphology. Furthermore, panoramic reconstructions derived from CBCT data, particularly cross-sectional sections, enable detailed analysis of mandibular cortical thickness as well as the organization and density of trabecular bone. Therefore, the evaluation of radiomorphometric indices using CBCT data provides more reliable results than conventional two-dimensional imaging methods[3–5].

The Bone Quality Index (BQI) is a radiomorphometric parameter that provides qualitative information regarding mandibular cortical and trabecular bone structures. BQI enables the assessment of bone quality based on the density and organization of the trabecular structure on cross-sectional images. BQI has been widely used for assessment of bone quality in implant dentistry and for the evaluation of age- and sex-related bone changes in bone structure[6].

The literature indicates that radiomorphometric indices have been predominantly evaluated using conventional panoramic radiographs and have mainly been investigated in relation to systemic factors. In contrast, studies assessing the effects of mandibular pathological lesions on bone morphology through these indices are limited. Furthermore, most existing studies have not comprehensively examined indices such as MCI, PMI, and BQI in conjunction with lesion etiology, localization, and their destructive or expansive effects on bone. This highlights the need for a more detailed investigation of the relationship between bone quality and lesion characteristics using three-dimensional imaging modalities[7].

Therefore, the present study aims to evaluate the association between the size of mandibular lesions and mandibular bone quality using the BQI based on CBCT images.

METHODS

The cohort represents a heterogeneous group of histopathologically confirmed mandibular lesions, including both odontogenic lesions and other central jaw lesions. We explicitly identify this heterogeneity as a methodological limitation. Regarding image orientation, BQI assessment was performed using standardized cross-sectional CBCT reconstructions to ensure reproducibility.

This retrospective radiographic study was conducted using archived records of 1000 patients who attended the Department of Oral and Maxillofacial Radiology, Faculty of Dentistry, Atatürk University, between January 2024 and August 2025. Cone-beam computed tomography images of 42 patients (18 males and 24 females) aged between 8 and 88 years (mean age: 43.12 years) were included in the study. A total of 49 mandibular lesions were retrospectively evaluated.

All lesions included in the study had histopathological diagnoses, which were confirmed based on the corresponding pathology reports. According to the histopathological examination results, the lesions were classified as:

- radicular cysts (n=15);
- ameloblastomas (n=13);
- odontogenic keratocysts (n=11);
- dentigerous cysts (n=5);
- central giant cell granulomas (n=2);
- residual cysts (n=1);
- calcifying epithelial odontogenic tumors (n=1); and
- ossifying fibroma (n=1).

The study protocol was approved by the Clinical Research Ethics Committee of Atatürk University (Decision No: 39; Session No: 05/2026; Date: 02 June 2026), and all procedures were conducted in accordance with the principles of the Declaration of Helsinki.

The inclusion criteria were the availability of diagnostic-quality CBCT images and the presence of a lesion in the mandible. Images in which the mandibular cortical or trabecular bone could not be adequately evaluated due to lesion-related alterations, images with significant artifacts, and scans in which radiomorphometric measurements could not be performed reliably were excluded from the study. In addition, patients with systemic diseases affecting bone metabolism, those receiving medications known to influence bone metabolism, individuals with a history of mandibular surgery, local bone diseases, or previous mandibular fractures were excluded.

All CBCT images were acquired using a NewTom VGi evo unit (QR S.r.l., Verona, Italy) following the manufacturer's recommended standard imaging protocols and in accordance with the ALARA principle. During image acquisition, patients were positioned with the Frankfurt horizontal plane parallel to the floor, and a head stabilization device was used to minimize motion artifacts. Patients were instructed to remain motionless throughout the scanning procedure. All metallic accessories were removed prior to imaging.

Imaging parameters were determined according to the manufacturer's standard protocol. The field of

view (FOV) was set at 16×16 cm, and the voxel size was 0.2 mm^3. Tube voltage (90–110 kVp) and tube current were automatically adjusted for each patient using the device's SafeBeam technology, without any manual intervention by the investigators. The scan time ranged from 18 to 26 seconds.

The acquired images were evaluated using multiplanar reconstruction (MPR) in the axial, sagittal, and coronal planes. Slice thickness was adjusted between 0.5 and 1 mm for image analysis.

Evaluation of mandibular bone quality using the Bone Quality Index

Mandibular bone quality was assessed on CBCT cross-sectional sections using the BQI. The BQI evaluation was based on the Lekholm and Zarb bone quality classification, as modified for CBCT by Rosas-Díaz et al.[8], which categorizes bone quality into four types (Type I–IV) according to the relative thickness and morphology of the cortical and trabecular bone in the mandibular body (Figures 1–4).

For BQI assessment, bone quality was evaluated on cross-sectional CBCT sections obtained from the ipsilateral side of the lesion. The evaluation was performed on the first adjacent bone section demonstrating preserved bone architecture and not directly affected by the lesion. Intact bone was defined as bone without radiographic evidence of lesion-related cortical perforation, cortical expansion, marked cortical thinning, or trabecular destruction. A fixed distance from the lesion border was not predetermined; instead, the nearest unaffected bone area was selected for evaluation. In cases of extensive lesions, the closest available region with preserved cortical and trabecular morphology on the same side of the mandible was used for BQI classification. Bone quality was classified according to the following criteria:

- Type I: Bone composed of homogeneous, dense, and compact cortical tissue. Trabecular bone is minimal or exhibits a highly dense appearance. This bone type is characterized by high bone density and a well-defined cortical structure (Figure 1);

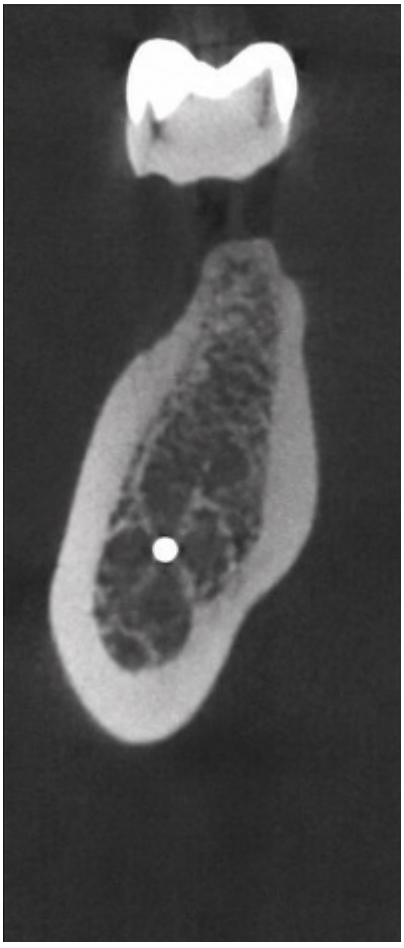

Figure 1. Homogeneous compact cortical bone (Type I).

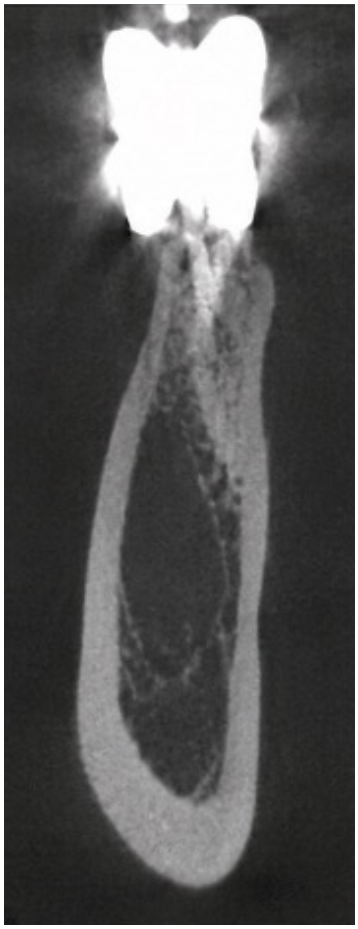

Figure 2. Thick cortical layer with dense trabecular bone (Type II).

- Type II: Thick cortical bone with a dense and well-organized trabecular structure (Figure 2);
- Type III: Characterized by a thinner cortical bone layer and a more loosely organized trabecular structure. Bone density is reduced, and the trabecular pattern appears less dense and more sparse compared with Type II bone quality (Figure 3);
- Type IV: Characterized by a very thin cortical layer and a low-density, sparse trabecular bone structure. This bone type is considered to exhibit the lowest bone density among all bone quality categories (Figure 4).

Assessment of lesion size

Lesion size was measured on digital panoramic reconstruction images generated from CBCT data. The anteroposterior diameter [mm] of each lesion was recorded and used for statistical analysis. In all cases, panoramic reconstruction images were generated using a 5-mm slab thickness. To ensure standardization, the same reconstruction parameters were applied to all images throughout the study (Figure 5).

All images were evaluated by a single investigator with 3 years of experience in oral and maxillofacial radiology under standardized viewing conditions in a low-light environment using a computer equipped with an LCD monitor available at the faculty. To minimize observer bias and misinterpretation, radiographic findings were confirmed on at least two consecutive sections. In addition, image evaluations were repeated at different time points to improve intraobserver consistency. Lesions were classified according to their localization within the mandible, their sizes were measured and included in the analyses, and the age and sex of all patients were recorded.

Statistical analysis was performed using IBM SPSS Statistics software (Version 20.0; IBM Corp., Armonk, NY, USA). Descriptive statistics were presented as frequencies and percentages (%). Relationships between

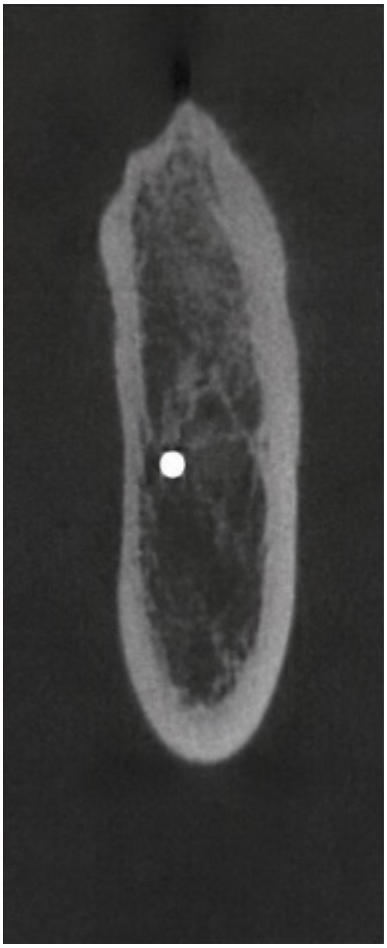

Figure 3. Thin cortical layer with moderately dense trabecular bone (Type III).



Figure 4. Very thin cortical layer with low-density trabecular bone (Type IV).



Figure 5. Measurement of the anteroposterior diameter of lesion on a CBCT-derived digital panoramic reconstruction image.

variables were assessed using Spearman's correlation analysis. Differences in BQI and lesion size between male and female patients were evaluated using the independent-samples t-test. A p-value of less than 0.05 was considered statistically significant for all analyses. Kappa statistics for agreement were used to assess the intra-observer reliability and were interpreted as follows:

- <0, poor agreement;
- 0.00–0.20, slight agreement;
- 0.21–0.40, fair agreement;
- 0.41–0.60, moderate agreement;
- 0.61–0.80, substantial agreement;
- 0.81–0.99, almost perfect agreement; and
- 1.00, perfect agreement.

RESULTS

No statistically significant relationship was found between lesion size and the mandibular BQI ($p>0.05$). However, a statistically significant association was observed between lesion size and lesion localization ($p=0.008$), with lesions located in the right mandible tending to be larger.

A positive and statistically significant correlation was found between BQI and age ($r=0.384$, $p=0.007$). Since higher BQI values indicate lower bone quality, this finding suggests that mandibular bone quality decreases with increasing age.

A significant sex-related difference was observed in bone quality ($p<0.001$), with female patients showing higher BQI values and consequently lower bone quality than males. However, lesion size did not differ significantly between sexes ($p>0.05$).

The intra-observer coefficient values showed high reliability for all lesion size and the BQI. The intra-observer coefficients were 0.87 (almost perfect agreement) for lesion size and 0.85 (almost perfect agreement) for the BQI.

DISCUSSION

The present study investigates whether lesion dimensions are associated with measurable differences in the radiographic characteristics of the surrounding mandibular bone, as represented by the BQI. There is a biologically plausible basis for examining this relationship, as mandibular lesions do not develop in an anatomically neutral environment. Their radiographic appearance and extent may be influenced by the structural characteristics of the host bone, while progressive remodeling associated with a lesion may alter the local radiographic appearance. Thus, the relationship should be considered potentially bidirectional. We emphasize that BQI is a qualitative radiographic classification reflecting local morphology and density, not an independent biological predictor of lesion growth. This study is exploratory in nature, aiming to investigate whether BQI demonstrates measurable variation according to lesion characteristics.

The present study evaluated the relationship between the size of lesions located in the mandible and the mandibular BQI. According to the findings, no statistically significant relationship was observed between lesion size and BQI. These findings suggest that mandibular bone quality, as assessed by BQI, may not be a major determinant of these lesions.

Radiomorphometric indices are widely used in the assessment of mandibular bone quality, and several studies have demonstrated their association with bone mineral density and trabecular bone structure. Horner and Devlin reported that indices reflecting mandibular cortical and trabecular characteristics may provide reliable information regarding systemic bone density[9]. In this context, BQI is considered an important parameter for the evaluation of bone quality. However, the absence of a significant association between BQI and lesion size in the present study indicates that bone quality alone is insufficient to explain variations in lesion dimensions.

In addition to BQI, several radiomorphometric indices, including the Mandibular Cortical Index (MCI), Panoramic Mandibular Index (PMI), and Mental Index (MI), have been used to assess mandibular bone quality. Previous studies have reported significant associations between these indices and bone mineral density, particularly in the screening of osteoporosis[10]. Nevertheless, because most of these indices are based on two-dimensional imaging modalities, they may not fully reflect bone microarchitecture. Therefore, three-dimensional imaging techniques such as CBCT may provide a more reliable assessment of bone quality.

Bone quality is defined by structural characteristics such as cortical thickness and trabecular density and is closely associated with biomechanical stability, particularly in implant dentistry. Reduced implant success rates have been reported in areas with poor bone quality, especially Type IV bone, due to thin cortical bone and low trabecular density[11]. In contrast, higher primary stability is generally achieved in Type I and Type II bone. However, this biomechanical relationship does not necessarily parallel the biological behavior and growth dynamics of these lesions[12,13].

The size of the lesions is influenced by multiple factors, including histopathological type, biological behavior, growth potential, and duration before diagnosis. While cystic lesions often exhibit an expansive growth pattern leading to cortical thinning and trabecular alterations, certain tumors may produce more aggressive bone destruction. Consequently, lesion size is likely determined by a complex interaction of biological factors rather than bone quality alone. The absence of a significant relationship between BQI and lesion size in the present study supports this multifactorial nature[2,14].

The response of bone tissue to these lesions depends not only on lesion size but also on lesion behavior and its interaction with surrounding tissues. Some lesions grow slowly, allowing adaptive bone remodeling, whereas others exhibit rapid and destructive growth patterns that may result in substantial bone loss. Increased osteoclastic activity, inflammatory mediator release, and bone remodeling processes are important contributors to these changes. Therefore, alterations in bone quality cannot always be directly attributed to lesion size, and the relationship between these variables appears to be biologically complex[2,14].

Although some previous studies have suggested a possible association between lesion expansion and alterations in bone density, the available evidence remains limited and inconsistent. In the present study, no significant association was observed between lesion size and BQI, indicating that lesion dimensions cannot be explained by bone quality alone.

The association between mandibular bone quality and systemic skeletal conditions has been extensively investigated. Taguchi et al.[15] demonstrated that mandibular radiographic indices are associated with osteoporosis and may facilitate the radiographic identification of reduced bone mineral density[15]. These findings suggest that BQI may reflect not only local bone characteristics but also systemic bone quality. However, the lack of an association between BQI and lesion size in the present study supports the notion that lesion dimensions are primarily influenced by local biological factors[15].

Regarding age-related changes, previous studies have reported reductions in bone mineral density and bone quality parameters with increasing age. Similarly, a significant relationship between age and BQI was observed in the present study, indicating lower bone quality in older individuals. This finding is consistent with previous reports demonstrating age-related deterioration in bone quality[16,17].

Male individuals exhibited significantly higher bone quality than female individuals. This finding may be explained by accelerated bone loss in women, particularly after menopause, as a consequence of decreased estrogen levels. The present findings are consistent with previous studies reporting sex-related differences in bone density and bone quality[15,18].

With regard to lesion localization, lesions located in the right mandible were found to be larger than those located on the left side. Although a statistically significant association was observed, this finding likely lacks clinical or biological significance. Given the retrospective nature of our cohort, this observation is most plausibly attributable to sample distribution and selection artifact rather than a true anatomical or pathological predisposition.

In addition, no significant association was observed between patient age and the anterior/posterior localization of the lesion, suggesting that lesion distribution within the mandible appears to be independent of age in the present study.

A major strength of the present study is that BQI assessment was performed using CBCT cross-sectional sections, allowing three-dimensional evaluation of bone quality. Compared with panoramic radiography, CBCT eliminates superimposition and distortion, enabling a more accurate assessment of bone morphology.

Several limitations of this study should be acknowledged. The retrospective design, relatively small sample size, and the inclusion of lesions with different histopathological characteristics and biological behaviors may restrict the generalizability of the findings. Furthermore, the effects of age, sex, and other systemic factors could not be completely eliminated. The use of a single linear anteroposterior measurement should be interpreted as a radiographic dimension rather than a complete representation of lesion volume. Secondary statistical findings, such as the association with mandibular side, should be considered exploratory and may represent chance observations. Future prospective, longitudinal studies with larger, lesion-specific cohorts are required to validate these preliminary findings.

CONCLUSIONS

Within the limitations of this study, no significant relationship was found between mandibular bone quality, as assessed by the BQI, and the size of these lesions. These findings suggest that lesion size is likely influenced by multiple biological and histopathological factors rather than bone quality alone. Nevertheless, BQI may serve as a useful adjunctive parameter in the assessment of mandibular bone quality. Further studies with larger sample sizes and more homogeneous lesion groups are required to clarify the relationship between bone quality and the biological behavior of these lesions.

ACKNOWLEDGMENTS

The authors thank the staff of the Department of Oral and Maxillofacial Radiology, Faculty of Dentistry, Atatürk University, for their support in accessing the archived CBCT records.

AUTHORS' CONTRIBUTIONS

NR: Conceptualization, Data curation, Formal Analysis, Writing – original draft. BÇ: Conceptualization, Formal Analysis, Supervision, Writing – review & editing. GNB: Data Curation, Formal Analysis, Writing – review & editing. All authors read and approved the final version of the manuscript.

CONFLICT OF INTEREST STATEMENT

Funding: The authors declare that no funds, grants, or other support were received during the preparation of this manuscript.

Competing interests: The authors have no relevant financial or non-financial interests to disclose.

DATA AVAILABILITY STATEMENT

The datasets generated and analyzed during the current study are available from the corresponding author on reasonable request.

REFERENCES

1. Stauber M, Müller R. Age-related changes in trabecular bone microstructures: Global and local morphometry. Osteoporosis International. 2006;17(4):616-26. https://doi.org/10.1007/s00198-005-0025-6
2. MacDonald-Jankowski DS. Keratocystic odontogenic tumour: Systematic review. Dentomaxillofac Radiol. 2011;40(1):1-23. https://doi.org/10.1259/dmfr/29949053
3. Scarfe WC, Farman AG. What is Cone-Beam CT and How Does it Work? Dent Clin North Am. 2008;52(4):707-30. https://doi.org/10.1016/j.cden.2008.05.005
4. Nackaerts O, Maes F, Yan H, Souza PC, Pauwels R, Jacobs R. Analysis of intensity variability in multislice and cone beam computed tomography. Clin Oral Implants Res. 2011;22(8):873-9. https://doi.org/10.1111/j.1600-0501.2010.02076.x
5. Pauwels R, Beinsberger J, Collaert B, Theodorakou C, Rogers J, Walker A, et al. Effective dose range for dental cone beam computed tomography scanners. Eur J Radiol. 2012;81(2):267-71. https://doi.org/10.1016/j.ejrad.2010.11.028
6. Drage NA, Palmer RM, Blake G, Wilson R, Crane F, Fogelman I. A comparison of bone mineral density in the spine, hip and jaws of edentulous subjects. Clin Oral Implants Res. 2007;18(4):496-500. https://doi.org/10.1111/j.1600-0501.2007.01379.x
7. Molteni R. Prospects and challenges of rendering tissue density in Hounsfield units for cone beam computed tomography. Oral Surg Oral Med Oral Pathol Oral Radiol. 2013;116(1):105-19. https://doi.org/10.1016/j.oooo.2013.04.013
8. Rosas-Díaz JC, Córdova-Limaylla NE, Palomino-Zorrilla JJ, Guerrero ME, Carreteros R, Cervantes-Ganoza LA, et al. Repeatability and Reproducibility of a Modified Lekholm and Zarb Bone Quality Classification Based on Cone Beam Computed

Tomography: An Observational Study. J Int Soc Prev Community Dent. 2024;14(4):278-86. https://doi.org/10.4103/jispcd.jispcd_291_21
9. Horner K, Devlin H. The relationship between mandibular bone mineral density and panoramic radiographic measurements. J Dent. 1998;26(4):337-43. https://doi.org/10.1016/s0300-5712(97)00020-1
10. Munhoz L, Morita L, Nagai AY, Moreira J, Arita ES. Mandibular cortical index in the screening of postmenopausal at low mineral density risk: a systematic review. Dentomaxillofac Radiol. 2021;50(4):20200514. https://doi.org/10.1259/dmfr.20200514
11. Gulsahi A. Bone Quality Assessment for Dental Implants. In: Turkyilmaz I, ed. Implant Dentistry - The Most Promising Discipline of Dentistry. London: IntechOpen; 2011. p. 437-52. https://doi.org/10.5772/16588
12. Esfahanizadeh N, Davaie S, Rokn AR, Daneshparvar HR, Bayat N, Khondi N, et al. Correlation between bone mineral density of jaws and skeletal sites in an Iranian population using dual X-ray energy absorptiometry. Dent Res J (Isfahan). 2013;10(4):460-6. https://doi.org/10.4103/1735-3327.118487
13. Peñarrocha M, Uribe R, Balaguer J. Immediate implants after extraction. A review of the current situation. Med Oral. 2004;9(3):234-42.
14. Kitisubkanchana J, Reduwan NH, Poomsawat S, Pornprasertsuk-Damrongsri S, Wongchuensoontorn C. Odontogenic keratocyst and ameloblastoma: radiographic evaluation. Oral Radiol. 2021;37(1):55-65. https://doi.org/10.1007/s11282-020-00425-2
15. Taguchi A, Tanimoto K, Suei Y, Otani K, Wada T. Oral signs as indicators of possible osteoporosis in elderly women. Oral Surg Oral Med Oral Pathol Oral Radiol Endod. 1995;80(5):612-6. https://doi.org/10.1016/s1079-2104(05)80158-1
16. Klemetti E, Kolmakov S, Kröger H. Pantomography in assessment of the osteoporosis risk group. Scand J Dent Res. 1994;102(1):68-72. https://doi.org/10.1111/j.1600-0722.1994.tb01156.x
17. Ito M, Nakata T, Nishida A, Uetani M. Age-related changes in bone density, geometry and biomechanical properties of the proximal femur: CT-based 3D hip structure analysis in normal postmenopausal women. Bone. 2011;48(3):627-30. https://doi.org/10.1016/j.bone.2010.11.007
18. Vári B, Győri F, Katona Z, Berki T. The Impact of Age and Body Composition on Bone Density among Office Worker Women in Hungary. Int J Environ Res Public Health. 2023;20(11):5976. https://doi.org/10.3390/ijerph20115976